



*CASE STUDY*

## **Early illness: a possible case of meningitis in a modern child from the wheel of *Santa Casa da Misericórdia* (Faro, Portugal)**

Joana Paredes<sup>1</sup>, Maria Teresa Ferreira<sup>1,2</sup>, Sofia N. Wasterlain<sup>1,2,3</sup>

<sup>1</sup> Department of Life Sciences, University of Coimbra, Portugal

<sup>2</sup> Forensic Sciences Centre – Instituto Nacional de Medicina Legal, IP, Portugal

<sup>3</sup> Research Centre for Anthropology and Health – University of Coimbra, Portugal

\*Corresponding author: [mtsferreira@yahoo.com](mailto:mtsferreira@yahoo.com)

*Artigo recebido a 14 de Fevereiro de 2014 e aceite a 21 de Fevereiro de 2014*

### ABSTRACT

The aim of the present study is the differential diagnosis of an uncommon pathological case. The subject under analysis is the skeleton of a child recovered from an archaeological intervention in Santa Casa da Misericórdia de Faro (Portugal). The excavation brought to light a cemetery (16<sup>th</sup> – 19<sup>th</sup> centuries) with three phases of funerary use, one of which was identified as corresponding to abandoned new-borns, received at the institution through the wheel mechanism.

One of the 51 immature individuals exhumed was a two year-old child, who presented unusual intracranial marks. All bones were examined under standardized lighting conditions by careful visual inspection, with the aid of a low-power microscope. The differential diagnosis of the lesions included several possible pathological conditions, namely anaemia, scurvy, rickets, and bacterial and tuberculous meningitis. However, after comparing the present case with the descriptions and

images of different types of cranial lesions, those seem to match the ones of bacterial meningitis. The postcranial evidences in the skeleton also match this diagnosis.

Considering the circumstances in which these children lived, orphanages with poor nutritional and hygienic conditions, exposure to pathogens was highly likely to occur. This historical fact could explain a case of meningitis.

*Keywords: Infectious disease; Non-adults; Orphanage; Growth; Paleopathology; Bioarchaeology.*

\*\*\*

## RESUMO

A intervenção arqueológica levada a cabo na Santa Casa da Misericórdia de Faro permitiu a escavação de um cemitério (séculos XVI-XIX) com três fases de ocupação. A mais recente correspondia às inumações de recém-nascidos e infantes abandonados na Roda dos Expostos dessa instituição. Foram recuperados os restos esqueléticos de 51 indivíduos não adultos, um dos quais apresenta várias lesões ósseas, intra-cranianas e pós-cranianas, que serão objecto de análise no presente artigo.

O esqueleto de uma criança de cerca de 2 anos foi sujeito a uma cuidadosa observação macroscópica auxiliada por uma lupa binocular. O diagnóstico diferencial das lesões observadas levou à consideração de várias condições patológicas específicas, como a anemia, o escorbuto, o raquitismo e as meningites bacteriana e tuberculosa. No entanto, o padrão e distribuição das lesões intra-cranianas apontam para um provável caso de meningite bacteriana, diagnóstico apoiado pelas lesões observadas ao nível do esqueleto pós-craniano.

As circunstâncias em que estas crianças terão vivido, um orfanato com fracas condições de higiene e uma nutrição pobre, terão favorecido uma maior exposição a agentes patogénicos. Por outro lado, estes indivíduos não seriam eficientemente protegidos pelo seu sistema imunitário imaturo, circunstâncias que poderão explicar este caso de meningite.

*Palavras-chave: Meningite; Não-adultos; Orfanato; Crescimento; Paleopatologia.*

## Introduction

During growth, individuals are exposed to several environmental stress factors (Lewis and Roberts, 1997). These are generally divided into two groups: infection and

malnourishment (Briend, 1998; Pinhasi, 2008). However, since it is not always possible to isolate the primary cause of growth retardation in a given population, epidemiological studies will depend largely

on non-specific stress indicators (Briend, 1998; Pinhasi, 2008). These are nonetheless usually analysed due to their relatively high rates of occurrence in skeletal samples, e.g. enamel hypoplasia, cribra orbitalia, porotic hyperostosis, non-specific periostitis and, more recently, endocranial lesions (Lewis and Roberts, 1997). Careful evaluation of the lesions morphology and their skeletal distribution often helps favouring one diagnosis at the expense of others.

The aim of the present study is to make the differential diagnosis of an uncommon pathological case, detected on the skeleton of an immature individual that was recovered from an archaeological intervention at the *Santa Casa da Misericórdia de Faro*, Portugal. This institution is a group of confraternities which is based on religious values and that has charitable purposes, divided in fourteen works of mercy (Sá, 1997; Abreu, 2000). Two of them - the burial of the dead and the care of abandoned children - are the basis of the formation of the osteological sample under analysis (Sá, 1997; Araújo, 2000; Fonte, 2004). The excavation brought to light the Santa Casa cemetery (16<sup>th</sup>-19<sup>th</sup> centuries) with various phases of funerary use, one of which comprised 51 burials of non-adults (with estimated ages ranging from foetal life to adolescence, although the majority aged less than 12 months), which corresponded to abandoned new-borns received at the institution through the foundling wheel mechanism – *Roda dos Expostos* (Corga and Ferreira, 2010). This device, built within the wall with a rotating door, was designed with the aim of abandoning ("expose", in the language of the time) new-borns without the

deliverer being seen by the receiver, maintaining the anonymity of the mother (Sá, 1988; Fonte, 2004; Franco, 2010). These 51 immature skeletons were studied as part of a Master thesis (Paredes, 2013), in which the pathological case reported in this paper was identified.

## Materials and Methods

The preservation of the remains was determined by calculating the Anatomical Conservation Index following Garcia (2005-2006). All the bones of Individual no.27 were examined under standardized lighting conditions by careful visual inspection, with the aid of a stereomicroscope. The age-at-death was estimated by dental calcification following Moorrees *et al.* (1963).

## Results

The skeleton of the immature individual presented an Anatomical Conservation Index of 62.2% thus preventing the analysis of all skeletal elements. The dentition was compatible with an individual who was approximately two years old ( $\pm 3$  months).

Unusual pathological lesions, namely vascular impressions on the inner surface of the parietals (Figure 1) and occipital bones, were observed. Moreover, most of the skull bones – the occipital (Figure 2), the parietals, the temporals, the right zygomatic, the right maxilla, the greater wings of the sphenoids (Figure 3), and the mandible (Figure 4) – showed porotic lesions. The same type of porotic lesions was also observed in the scapulas (Figure 5), right humerus, femur,

and tibias. In the case of the right humerus and the femurs, this porosity was associated with cribra humeralis (Figure 6) and cribra femoralis.




Figure 1. Endocranial lesions in the left parietal.

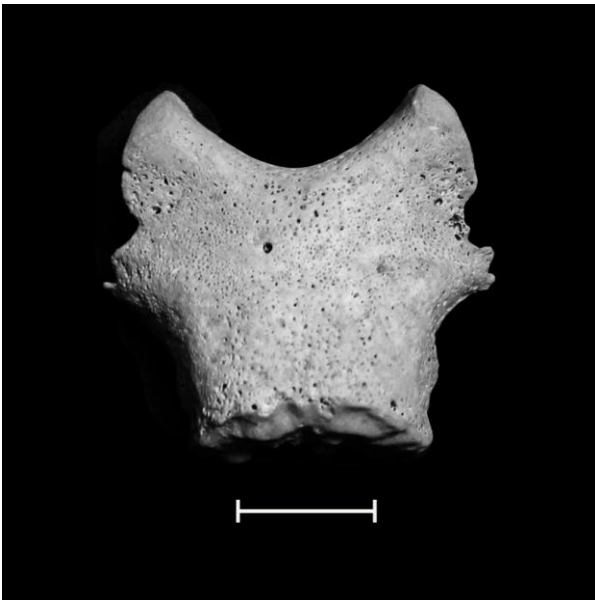


Figure 2. Porotic lesions in the pars basilaris (inferior view).




Figure 3. Porotic lesions in the greater wings of the sphenoid (inferior view).

### Discussion

The differential diagnosis of the lesions was coincident with several possible pathological conditions, namely anaemia, scurvy, rickets, and meningitis.

Anaemia: Skeletal changes associated as part of a generalised syndrome called porotic hyperostosis, characterized by porous lesions of the ectocranium (mainly on the frontal, parietal and occipital bones). When the pitting is located on the superior wall of the orbit, it is known as cribra orbitalia (Nathan and Haas, 1966; Roberts and Manchester, 2005; Mays, 2008). The porosity of the surface results in marrow hyperplasia (Mays, 2008).

The cranial lesions morphology and distribution of individual no.27 do not correspond to the typical features of anaemia. Also, the absence of cribra orbitalia does not favour such diagnosis.

Scurvy: The most frequent and characteristic changes in the growing skeleton are due to haemorrhage (Ortner and Ericksen, 1997; Mays, 2008), which may stimulate the periosteum to produce new bone. This

results in locally increased bone porosity to provide pathways for blood vessels (Ortner and Ericksen, 1997; Roberts and Manchester, 2005; Mays, 2008). The most common locations are the external surface of the skull vault, the orbital walls, the sphenoid (Mays, 2008), the maxilla, the hard palate, the scapulae, and the metaphyses of long bones (Ferreira, 2002; Mays, 2008). Cranial marks consist in the development of small pores or in the deposition of new bone over a normal underlying cortical bone (Mays, 2008).

The location of porotic lesions in individual no.27 is consistent with scurvy, but the morphology of the cranial marks and the absence of reaction of the periosteum turn such condition unlikely.




Figure 4. Porotic lesions in a mandible fragment (left lateral view).

Rickets: The bone changes consist of inadequate mineralization of newly deposited bone during growth (Burland, 1918; Mays *et al.*, 2006) due to vitamin D deficiency (Burland, 1918; Roberts and

Manchester, 2005; Mays, 2008), leading to porosity and roughness of the bone, especially near the growth plates (Mays *et al.*, 2006). The mechanical forces acting upon a weakened skeleton may lead to multiple bone deformities, including the spreading and concavity of the metaphyses and the bending of the diaphysis of long bones (Roberts and Manchester, 2005; Mays, 2008). Cranial bone surfaces may be spicular, since superficial pores are relatively larger and represent voids as a result of imperfect mineralization of a growing surface rather than transmitting blood vessels (Mays, 2008).

Apart from porosity in some skull bones, some diaphyses of long bones, and both scapulas, there are no deformities of the postcranial elements of individual no.27 that may be related to rickets.

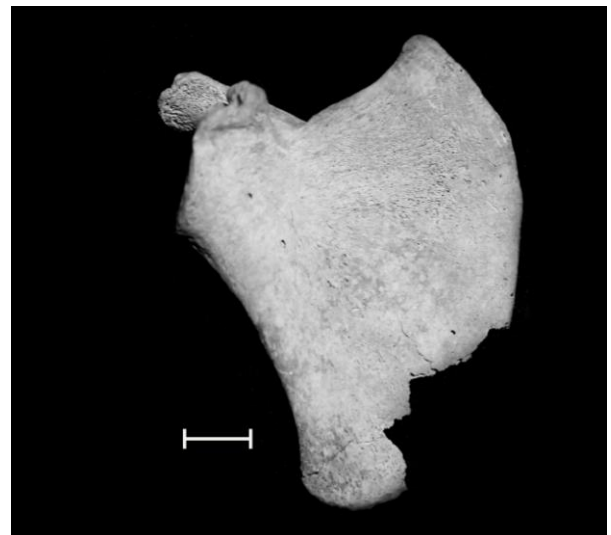
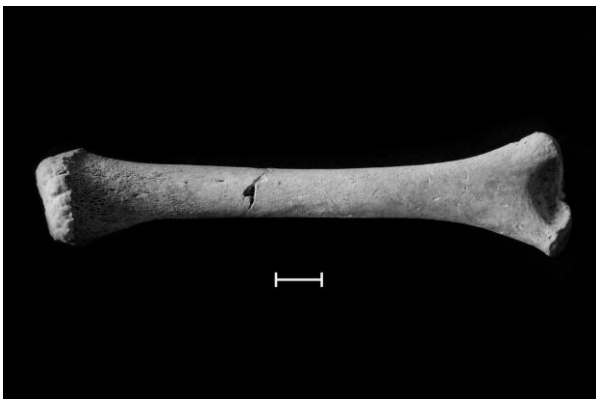

Figure 5. Porotic lesions in the right scapula (anterior view).

Meningitis: It is an acute inflammation of the meninges, the membranes covering the brain (cerebral), the spinal cord (spinal) or both

(Schultz, 2001; Roberts and Manchester, 2005), associated with several causes, being bacterial meningitis and tuberculous (TB) meningitis two of the main forms (Roberts and Buikstra, 2003). In areas of the skull vault affected by a focus of relatively large meningeal inflammation, characteristic impressions of atypical blood vessels can occur (Roberts and Buikstra, 2003). Vestiges of TB meningitis are characterized not only by the changes described above, but also by a relatively small granular impression, whose diameter varies between 0.5 and 1.0 mm, which may be filled at the bottom with lamellar bone. These impressions, usually presented in clusters, are situated on the endocranial face of the base and sometimes on the lateral wall of the skull and the cerebral fossa of the occipital bone (Schultz, 2001; Roberts and Buikstra, 2003). They are caused by pressure atrophy of tuberculars (Roberts and Buikstra, 2003).



**Figure 6.** Cribra humeralis in the right humerus (posterior view).

The cranial lesions observed in individual no.27 match the ones produced by meningitis. The absence of small

granulomata and arachnoid granulation favours the bacterial variant hypothesis at the expense of the tuberculous one. Postcranial evidences in the skeleton support this diagnosis, presenting themselves as signs of infection.

### Conclusion

Differential diagnosis of the endocranial lesions present in a two year-old child led to the consideration of bacterial meningitis as the most probable cause. The existence of several woven and porosity signs throughout the rest of the skeleton is coherent with an infectious condition. Bearing in mind the environment where the foundling wheel children lived – orphanages with poor nutritional and hygienic conditions (Sá, 1997) – exposure to pathogens was highly likely to occur. Besides, immature individuals would not be efficiently protected by their immune system. These circumstances could explain a case of meningitis.

### Acknowledgements

*The authors would like to thank Centro de Investigação em Antropologia e Saúde, Centro de Ciências Forenses, Dryas Arqueologia Lda., Styx, estudos de Antropologia Lda., and Ana Eduarda Sereijo. Finally, the authors would like to thank the editor of the journal and the anonymous reviewers whose suggestions allowed us to improve the manuscript.*

## References

- Abreu, L. 2000. Purgatório, Misericórdias e caridade: condições estruturantes da assistência em Portugal (séculos XV-XIX). *Dynamis: acta hispanica ad medicinae scientiarumque historiam illustrandam*, 20: 395-415.
- Araújo, M. 2000. Dar aos pobres e emprestar a Deus: as Misericórdias de Vila Viçosa e Ponte de Lima (séculos XVI-XVIII). Barcelos, Companhia Editora do Minho.
- Briend, A. 1998. Infection. In: Ulijaszek, S.J.; Johnston, F.E.; Preece, M.A. (eds.) *The Cambridge encyclopedia of human growth and development*. Cambridge, Cambridge University Press: 334-346.
- Burland, C. 1918. An historical case of rickets. *Practitioner*, 100: 391-395.
- Corga, M.; Ferreira, M.T. 2010. A acção caritativa da Santa Casa da Misericórdia de Faro: História e Bioarqueologia da 7ª obra corporal. *Xelb*, 10: 515-529.
- Ferreira, M.T. 2002. A scurvy case in a infant from Monte da Cegonha (Vidigueira – Portugal). *Antropologia Portuguesa*, 19: 57-63.
- Fonte, T. 2004. *No limiar da honra e da pobreza: A infância desvalida e abandonada no Alto Minho (1698-1924)*. Tese de Doutoramento em História, Instituto de Ciências Sociais, Universidade do Minho.
- Franco, R. 2010. *Órfão na Colónia*. [Online]. Revista de História. [Acedido em 04-12-2012]. Available in: <http://www.revistadehistoria.com.br/secao/artigos-revista/orfao-na-colonia>
- Garcia, S. 2005-2006. Conservação diferencial dos esqueletos humanos da série medieval de S. Martinho (Leiria): implicações para a paleodemografia e para a paleopatologia. *Antropologia Portuguesa*, 22/23: 273-294.
- Lewis, M.; Roberts, C. 1997. Growing Pains: The Interpretation of Stress Indicators. *International Journal of Osteoarchaeology*, 7: 581-586.
- Mays, S. 2008. Metabolic Bone Disease. In: Pinhasi, R.; Mays, S. (eds.) *Advances in Human Palaeopathology*. New York, Wiley-Liss: 215-251.
- Mays, S.; Brickley, M.; Ives, R. 2006. Skeletal Manifestations of Rickets in Infants and Young Children in a Historic Population from England. *American Journal of Physical Anthropology*, 129: 362-374.
- Moorrees, C.; Fanning, E.; Hunt, E. 1963. Age variation of formation stages for ten permanent teeth. *Journal of Dental Research*, 42: 1490-1502.
- Nathan, H.; Haas, N. 1966. "Cribra orbitalia" - A bone condition of the orbit of unknown nature. Anatomical study with etiological considerations. *Israel Journal of Medical Sciences*, 2(2): 171-191.
- Ortner, D.; Ericksen, M. 1997. Bone changes in the human skull probably resulting from scurvy in infancy and childhood. *International Journal of Osteoarchaeology*, 7: 212-220.
- Paredes, J. 2013. *A Infância Moderna Exposta nos Ossos: Caracterização Biológica e Paleopatológica numa Amostra Não Adulta da Roda da Santa Casa da Misericórdia de Faro*. Dissertação de Mestrado em Evolução e Biologia Humanas, Departamento de Ciências da Vida, Faculdade de Ciências e Tecnologia, Universidade de Coimbra.
- Pinhasi, R. 2008. Growth in Archaeological Population. In: Pinhasi, R.; Mays, S. (eds.) *Advances in Human Palaeopathology*. New York, Wiley-Liss: 363-380.
- Roberts, C.; Buikstra, J. 2003. *The Bioarchaeology of Tuberculosis*. Gainesville, University Press of Florida.
- Roberts, C.; Manchester, K. 2005. *The Archaeology of Disease*. 2<sup>nd</sup> edition. New York, Sutton Publishing Limited.
- Sá, I. G. 1988. Abandono de crianças, infanticídio e aborto na sociedade portuguesa tradicional através das fontes jurídicas. *Penélope: Fazer e Desfazer a História*, 8: 76-89.
- Sá, I. G. 1997. *Quando o rico se faz pobre: Misericórdias, Caridade e Poder no Império Português, 1500-1800. Coleção Outras Margens*. Lisboa, Comissão Nacional para as Comemorações dos Descobrimentos Portugueses.
- Schultz, M. 2001. Paleohistopathology of Bone: A New Approach to the Study of Ancient Diseases. *Yearbook of Physical Anthropology*, 44: 106-147.